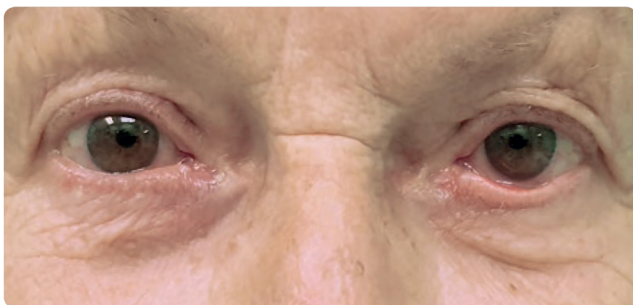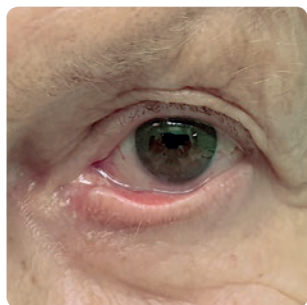


ECTROPION TREATMENT

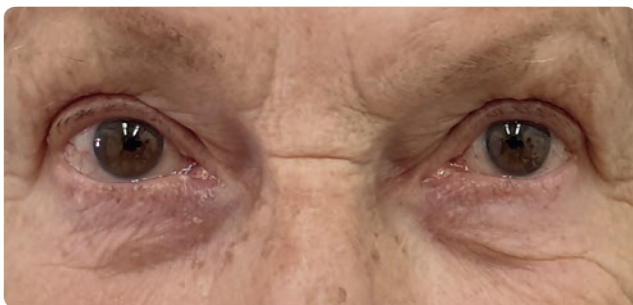
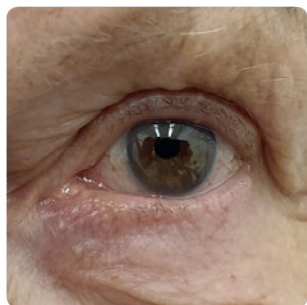with **JETT** PLASMA LIFT MEDICAL



Combination treatment of surgery and JETT PLASMA. Woman, 91 y/o, surgery without sufficient effect. Two weeks after operation JETT PLASMA was applied on the inside of the eyelid in place of ectropion for additional skin retraction. Results are more than satisfying.



Before



1 month after

Courtesy to MUDr. Marie Petrikovitsova, Military Hospital Brno, Czech republic